

PRACTICE REPORTS

B 124

of
Prof. Dr. med. R. Werner
Specialist: neck noses ears physician
Energy medicine professional

06.01.2004

Patient: Mrs. / Mr. Lutz-Uwe Tr. 39 years

Diagnosis: **Optic nerve Inflammation - both sides**

Anamnesis:

Since years decreasing condition of the vision, patient can not read letters of any size any more, reading is impossible and he is already learning the Braille in a braille school.

Therapy:

The patient begins in April 2003 with PERTH home treatment (acc. To Prof. Dr. Werner). The treatment is performed with PERTH Professional, 3 times a day, level 5 to 7 for 30 to 55 minutes per session. Permanently changing program P2 and P1. The patient is using the mat and the head applicator.

Result: In August 2003, four month later, the patient can read normal big letters. At the 8th Symposium of EMS Berlin at Sept. 20th 2003 he can visualize the projected pictures on the wall-screen and he can read the writing. The patient is crowded by Eye doctors during the break and questioned about his current subjective condition.

Appendix: His Eye doctor rejects to believe the vision improvement, because:
This is impossible...

signed by Prof. Dr. med. R. Werner

Translation of the original, signed by the medical professional

PRACTICE REPORTS

B 125

of
Dr. med. U. Koss-Wellbrock
Spezialist for eye diseases
Ollenhauerstr. 136
13403
Berlin

22.05.2005

Patient: Mrs. M. Fetzer

Diagnosis:

Open angle Glaucoma right eye with degeneration of the retina.

Anamnesis:

The patient noticed that she could not see anymore in the peripheral areas. The left eye was invariable in its vision. She went to the eye doctor who diagnosed.

Findings: Massive visual field losses in the peripheral areas of the retina of the right eye. (see findings of 19.10.2004 below)

Therapy:

Since 6 month, starting with the date of the diagnosis (Oct. 19th 2004), the treatment in home therapy with the PERTH system according to Prof. Dr. Werner took place. The patient used the programs P3, P2 and P1 in combination. In the morning, PERTH with the pillow applicator, Level „2-4“ for 15 minutes, noon and evenings with the head applicator, Program „P2“ and „P1“ daily changing on Level 1 for 16 minutes.

Result: The vision of the right eye has dramatically increased during the last 6 month PERTH therapy.

Findings: Significant increase of the visual field due to an obvious regeneration of the cells in the retina of the right eye. (see findings of Apr. 29.2005 below)

Signed by Dr. med. U. Koss-Wellbrock
Eye doctor

Translation of the original signed by the medical professional

19.10.04 (1)

Einzeifeldanalyse

Auge: Rechts

Name: FETZER.M.

ID:

Geb: 20-04-43


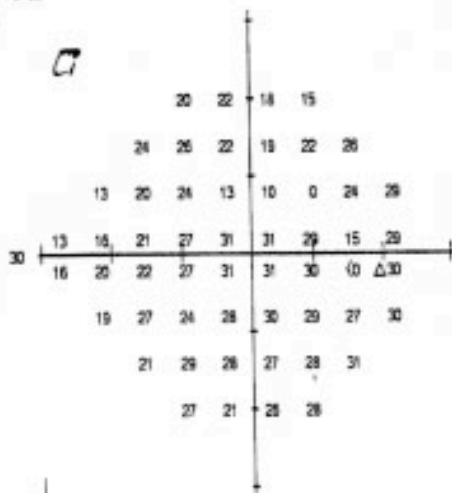
Zentral 24-2 Schwellentest

Fixationskontr.: Blindspot
Fixationsmarke: Zentral
Fixationsverluste: 3/18
False POS Errors: 4 %
False NEG Errors: 9 %
Testdauer: 07:04
Fovea: AUS

Prüffleck: III, Weiß
Hintergrund: 31,5 ASB
Strategie: SITA-Standard

Pupillendurchmesser:
Visus:
RX: DS DC X

Datum: 19-10-04
Zeit: 13:04
Alter: 61



Einzeifeldanalyse

Auge: Rechts

29.04.05

Name: FETZER.MARGIT

ID:

Geb: 20-04-1943

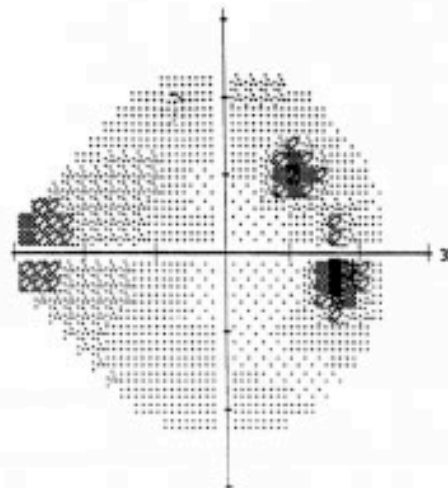
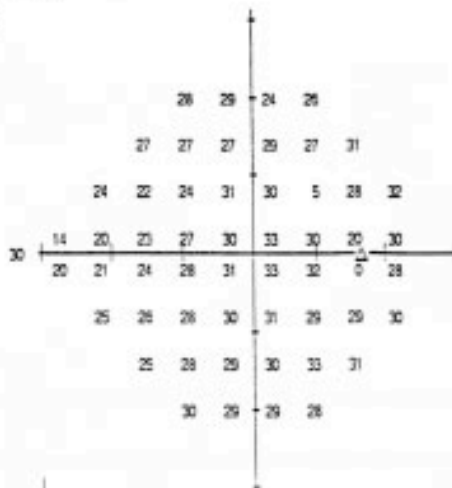
Zentral 24-2 Schwellentest

Fixationskontr.: Blickr./Blinder Fleck
Fixationsmarke: Zentral
Fixationsverluste: 8/17 xx
Falsch POS Fehler: 13 %
Falsch NEG Fehler: 10 %
Testdauer: 07:13
Fovea: AUS

Prüffleck: III, Weiß
Hintergrund: 31,5 ASB
Strategie: SITA-Standard

Pupillendurchmesser:
Visus:
RX: DS DC X

Datum: 29-04-2005
Zeit: 12:01
Alter: 62



© 1994-97 Humphrey Instruments
HFA II 730-1817-Rev. A8

Dr. med. Ursula Koss-Wellbrock
Augenärztin

Dr. Ursula Koss-Wellbrock